

surgery

internal medicine

emergency & critical care

dermatology

radiology, ultrasound & CT scan

In an effort to achieve clean surgical margins, aggressive removal of cancerous tumors often results in large tissue defects. **Single-Pedicle flaps** are used to reconstruct skin and tissue defects located at or below the elbow or knee.

Single - Pedicle Flap

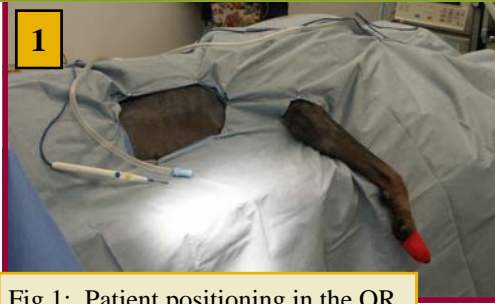

Fig.1: Patient positioning in the OR.

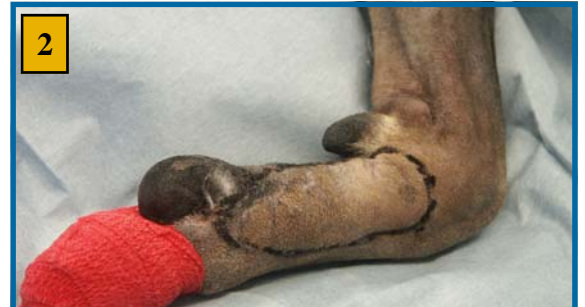

Fig.2: This patient had "dirty" margins following removal of a soft tissue sarcoma involving the lateral digit of the right front foot. Pre-surgical planning indicates the involved area to be excised.

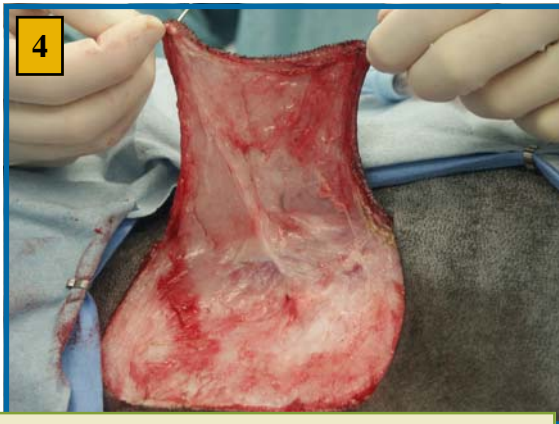


Fig.4: Preparation of the single-pedicle direct flap.

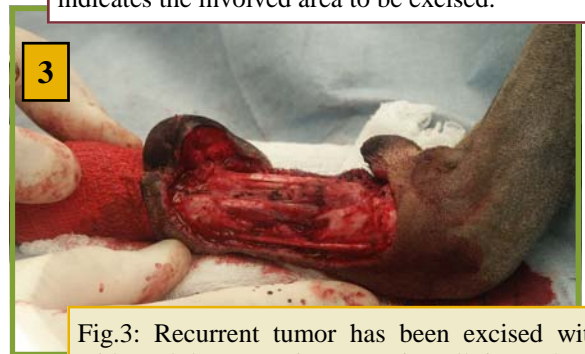

Fig.3: Recurrent tumor has been excised with wide and deep margins removing all tissue down to the flexor tendons and leaving a large defect.

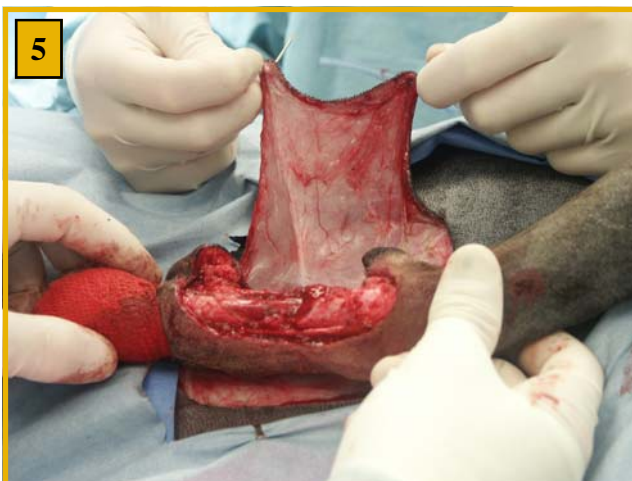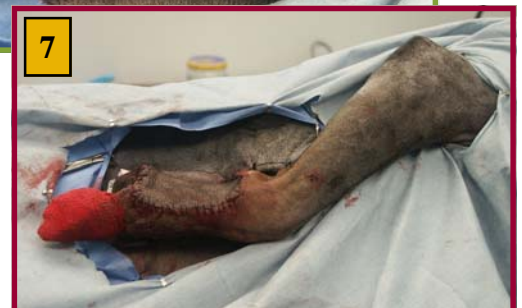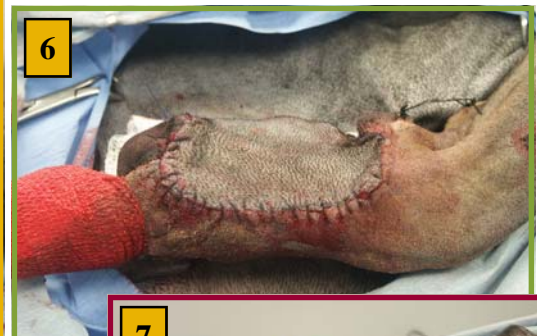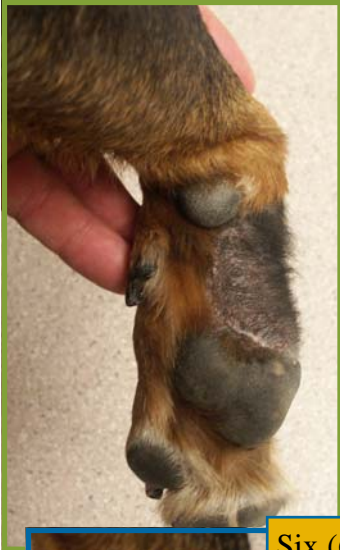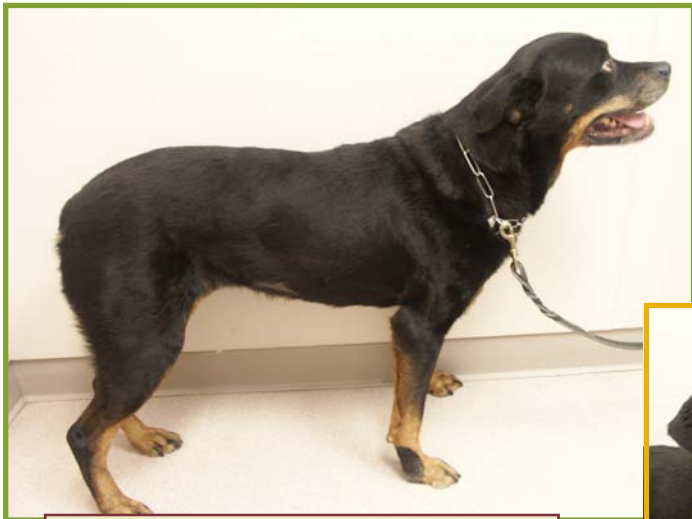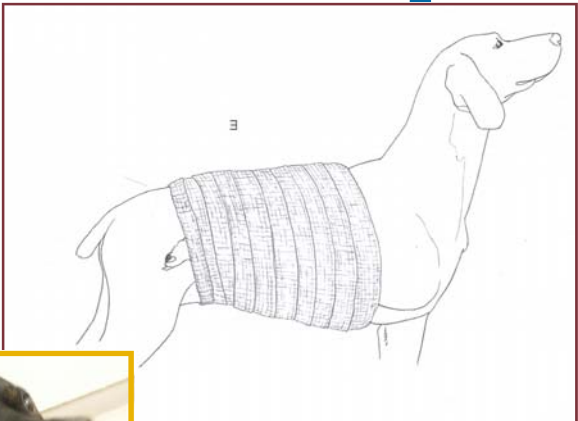
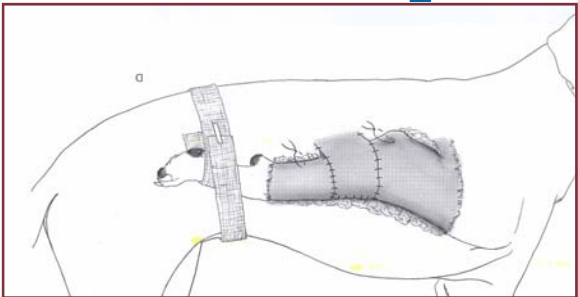
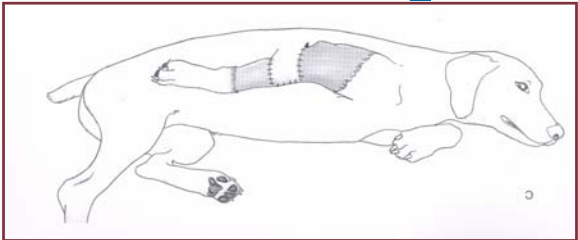


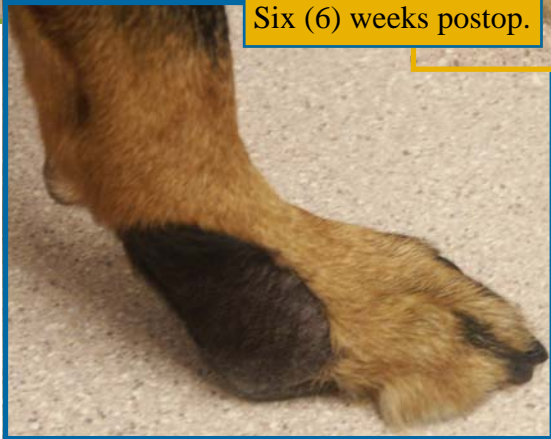Fig.5: Positioning of the flap over the defect by bringing the right front leg up and along side the lateral thorax and abdominal wall.





Six (6) weeks postop.



6 weeks postop:

- Excellent flap healing and incorporation
- Clean surgical margins
- Normal limb function and weight bearing

Figures: "Atlas of Small Animal Reconstructive Surgery" MM Pavletic

WHEAT RIDGE OFFICE

3695 Kipling St., Wheat Ridge, CO 80033
Tel 303-940-1239 • Fax 303-420-8360

WESTMINSTER OFFICE

945 W 124th Av, Westminster, CO 80234
Tel 303-350-4733 • Fax 303-350-4734

BOULDER OFFICE

1658 30th ST, Boulder, CO 80301
Tel 720-974-5802 • Fax 303-440-0649