



Wheat Ridge  
Veterinary Specialists

internal medicine

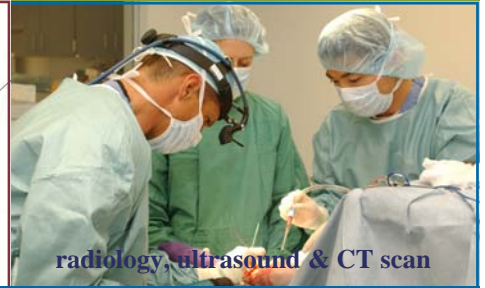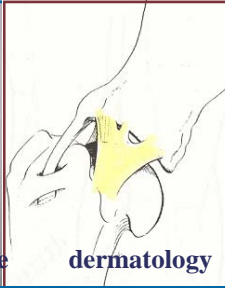
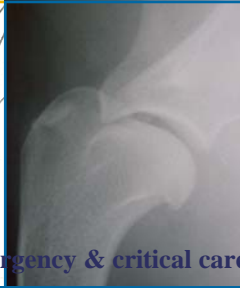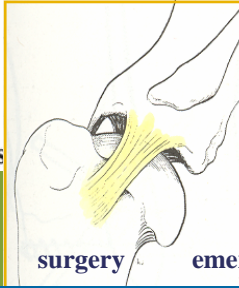
surgery

emergency & critical care

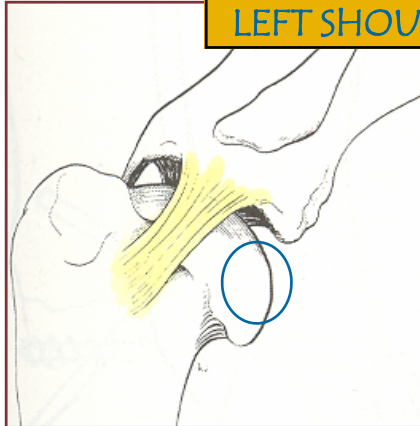
dermatology

radiology, ultrasound & CT scan

Expertise You Can Trust.

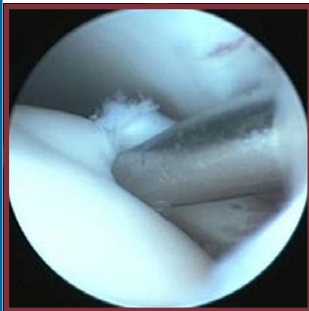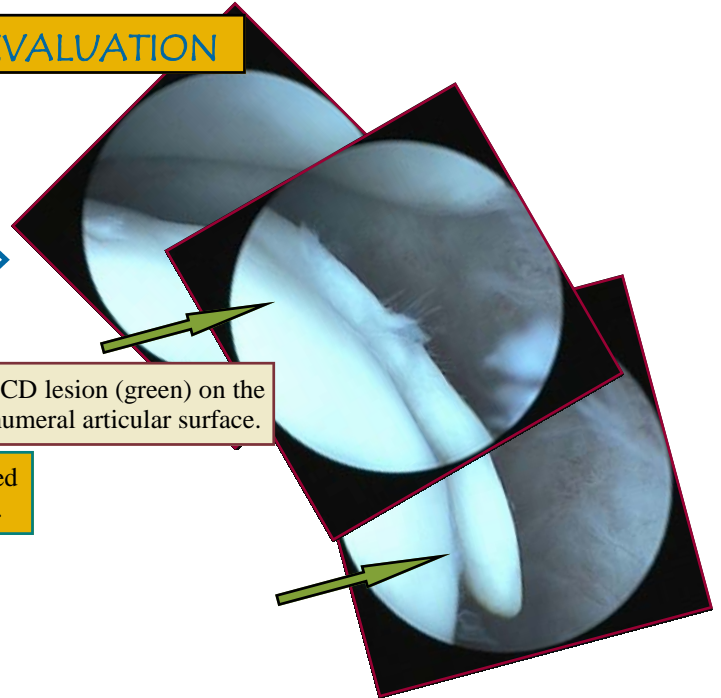


## LEFT SHOULDER EVALUATION

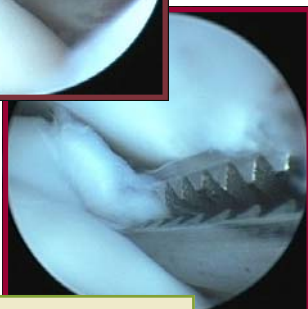

Lateral view of the left shoulder. OCD lesion located on the caudal humeral articular surface (blue circle).

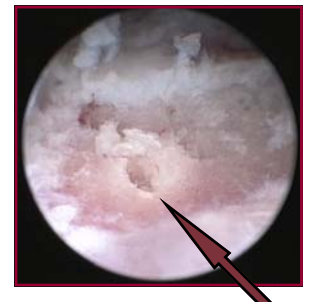
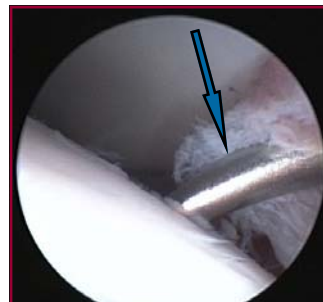
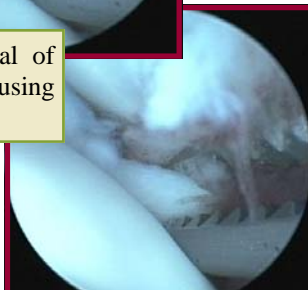Large OCD lesion (green) on the caudal humeral articular surface.



Mobilization and removal of the cartilage (OCD) flap using arthroscopic forceps.



Removal of additional damaged cartilage using an arthroscopic curette.



Microfracture instrument (blue) used to puncture the subchondral bone plate (red) and promote formation and adherence of a new cartilage surface.

**Osteochondrosis:** an alteration of cell differentiation and maturation in the metaphyseal growth plates and articular cartilage.

**Osteochondritis Dissecans:** a progression of osteochondrosis in which a dissecting flap of articular cartilage develops and is usually associated with inflammatory joint changes.

# Shoulder • OCD