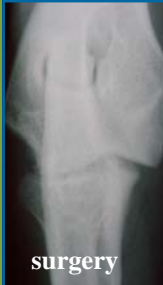


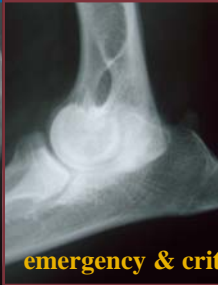
Wheat Ridge
Veterinary Specialists

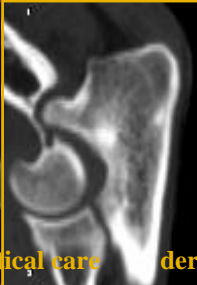internal medicine



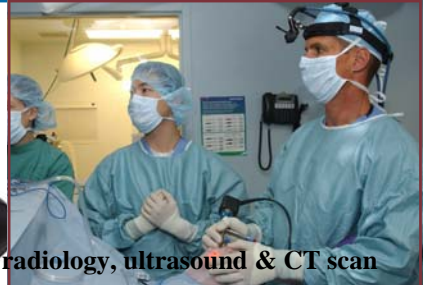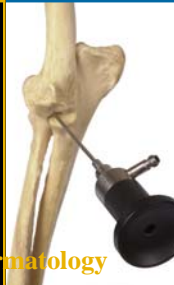
surgery



emergency & critical care



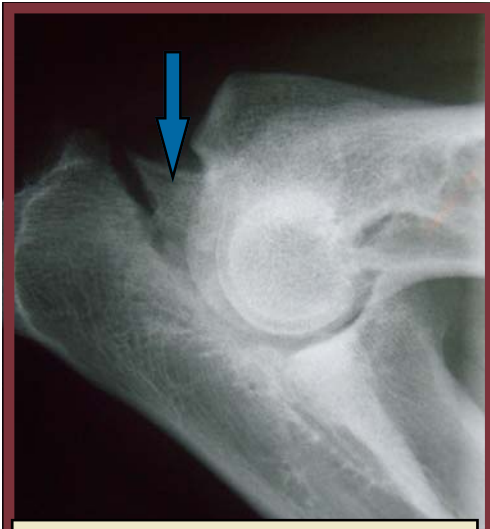dermatology



radiology, ultrasound & CT scan

Expertise You Can Trust.

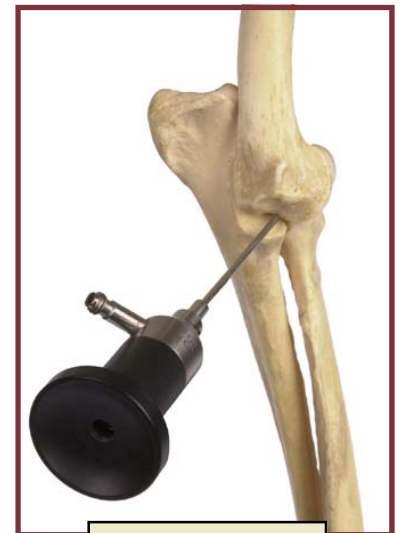Elbow Dysplasia • UAP



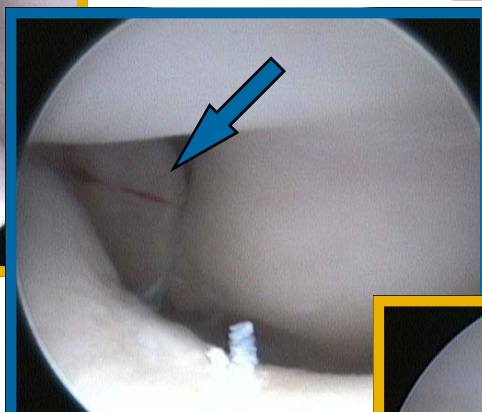
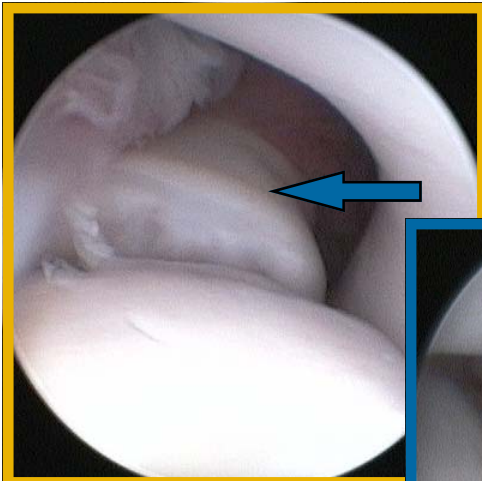
Lateral x-ray view showing **UAP** (blue) and moderate osteoarthritis in the joint.

Ununited Anconeal Process (UAP)

This condition usually develops at 5-6 months of age with failure of the anconeal process to fuse with the main portion of the olecranon. This condition is thought to result from a "poor fit" and incongruent joint with pressure on the anconeal process. Early surgical intervention with arthroscopy to evaluate the medial compartment of the joint coupled with a dynamic ulnar osteotomy to relieve pressure on the UAP is recommended and usually results in successful fusion of the UAP.



Arthroscopic view
Left Elbow



Panoramic view of the ulnar semilunar notch and medial articular surface of the left elbow showing an **Ununited Anconeal Process (UAP)** (blue). This condition is frequently associated with other joint pathology, such as a **Fragmented Medial Coronoid Process (FCP)** as can be seen to the right (green). Excoriations (grade 2 cartilage lesions) are visible on the articular surface of the medial humeral condyle as a result of repeated trauma from the loose FCP

