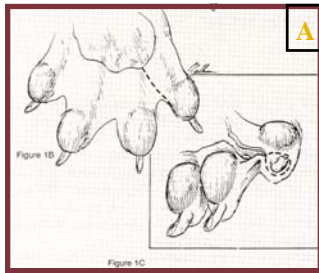
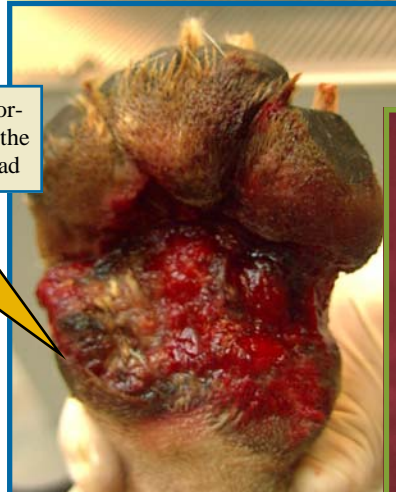


The **Digital Pad Transposition** technique (or Digit Fillet) can be used in severe trauma cases resulting in loss of the primary weight-bearing pad.

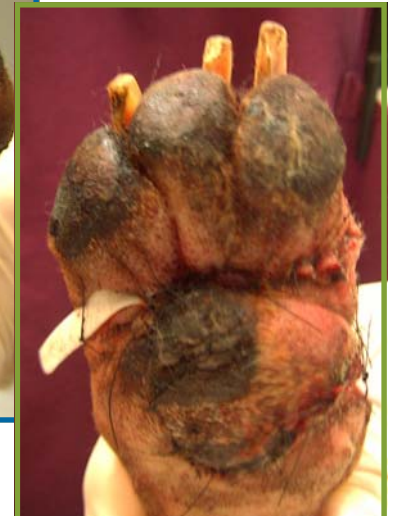Foot Reconstruction - Digit Fillet



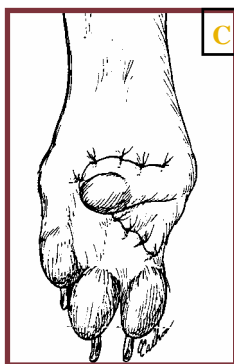
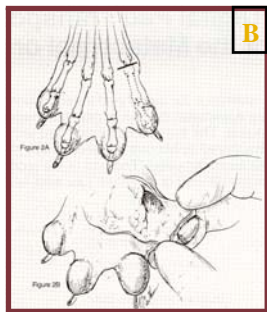
Remaining portion (10%) of the metacarpal pad



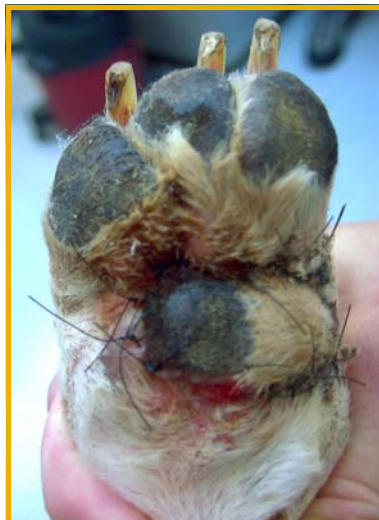PREOPERATIVE: traumatic injury to the left front foot resulting in 90% destruction of the metacarpal pad (primary weight-bearing pad)



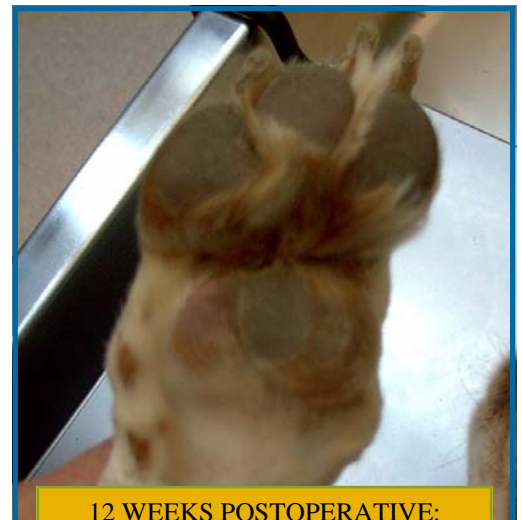IMMEDIATE POSTOPERATIVE: fillet of the 5th digit with digital pad transposition



A, B, C
DIGIT FILLET TECHNIQUE



2 WEEKS POSTOPERATIVE: viable pad surface



12 WEEKS POSTOPERATIVE: healed pad surface, successful digital pad transposition, hypertrophy of transferred and residual pad tissue.

Wheat Ridge Veterinary Specialists

WHEAT RIDGE OFFICE

3695 Kipling St., Wheat Ridge, CO 80033
Tel 303-940-1239 ● Fax 303-420-8360

WESTMINSTER OFFICE

945 W 124th Av, Westminster, CO 80234
Tel 303-350-4733 ● Fax 303-350-4734

BOULDER OFFICE

1658 30th ST, Boulder, CO 80301
Tel 720-974-5802 ● Fax 303-440-0649